



QANUN MEDIKA

JURNAL KEDOKTERAN FKUM SURABAYA

<http://journal.um-surabaya.ac.id/index.php/qanunmedika>



Research Article

Nephroprotective effect of virgin coconut oil in *Plasmodium berghei* ANKA infected Balb/c mice

Syafarinah Nur Hidayah Akil^{1,2*}, Heny Arwati³, Puspa Wardhani⁴, Priangga Adi Wiratama⁵

1) Postgraduate Student, Basic Medical Science, Universitas Airlangga

2) Department of Parasitology, Faculty of Medicine, Universitas Muhammadiyah Surabaya

3) Department of Parasitology, Universitas Airlangga

4) SMF/ Department of Clinical Pathology, RSUD Dr. Soetomo – Faculty of Medicine, Universitas Airlangga

5) SMF/ Department of Anatomical Pathology, RSUD Dr. Soetomo – Faculty of Medicine, Universitas Airlangga

ARTICLE INFO

Submitted : 14th August 2020

Accepted : 04th May 2021

Published : 25th July 2021

Keywords:

malaria, kidney, virgin coconut oil

*Correspondence:

syafarinahnurhidayah@fk.um-surabaya.ac.id

This is an Open acces article under the CC-BY-NC license



ABSTRACT

Malaria is a parasitic infectious disease caused by *Plasmodium*, which remains a world health problem with an estimated 219 million cases worldwide. In severe malaria infection, several organs of the body can be affected, including the kidneys. One of the pathophysiology associated with the worsening of this disease is oxidative stress. The use of antioxidants is expected to prevent this, and one product that has a high antioxidant content is virgin coconut oil (VCO). This study aimed to analyze the effect of VCO on the kidney in *Plasmodium berghei* ANKA-infected mice. This study was an *in vivo* laboratory experimental study with a randomized post-test only control group design using 35 BALB/c mice infected with *P. berghei* ANKA, weighing 20-30 grams. VCO with the Javara® brand is used with doses of 1, 5, and 10 ml/kg body weight (kgBW)/ day. The parameter assessed were levels of BUN, creatinine, and renal histopathological changes. The administration of VCO on the treated group shows minimal tubular necrosis and glomerulonephritis compared to the negative control group. The BUN and creatinine levels in the treated group were also lower than the negative control group. The results showed that VCO has a nephroprotective effect against *P. berghei* ANKA infection in mice.



INTRODUCTION

Malaria remains one of the essential protozoan diseases in the world (WHO, 2018). This tropical disease still remains a public health problem in several countries, including Indonesia (Kemenkes RI, 2016; WHO, 2015). The annual death rate because of this disease is still over a million, especially affecting children below five years old and pregnant women.

The primary pathogenesis mechanism in this infection is the hemolysis of erythrocytes infected with *Plasmodium*, which releases malaria merozoites and endotoxins (consisting of hemozoin complexes and parasitic DNA), thereby stimulating the host immune response (Phillips et al., 2017). Another pathogenesis of severe malaria is sequestration (cytoadherence and rosetting) which causes microvascular obstruction in vital organs (such as liver, kidney, and brain) and rosetting. This phenomenon results in disruption of cytokine and nitric oxide regulation, which can cause or aggravate local and systemic inflammation (Harijanto et al., 2016). The kidney is one of the organs that can experience severe malaria (WHO, 2015). As many as 40% of patients infected with *P. falciparum* can experience kidney complications in the form of acute kidney injury (AKI) (Plewes et al., 2014). Several factors that contribute to AKI are hypovolemia, vasoconstriction, hemolysis, parasitemia, and microcirculation dysfunction (Silva Junior et al., 2017). Impaired kidney function is characterized by increased levels of blood urea nitrogen (BUN) and creatinine ((Isa et al., 2013; Kalia et al., 2015). Kidney histology research in malaria shows acute tubular necrosis, glomerulonephritis, and interstitial nephritis (Akil, 2019; Koopmans et al., 2015).

The artemisinin combination therapies are the first-line treatment for malaria in endemic countries; however, resistance is reported

(Menard & Dondorp, 2017). Many studies on the development of herbal medicines for malaria therapy include pathophysiological modifications of oxidative stress by using antioxidants. One product that contains many antioxidants is virgin coconut oil (VCO) which is derived from fresh coconut or *Cocos nucifera* produced without heating or adding chemicals (Durasevic et al., 2019). High antioxidant content can reduce fat peroxidation and reduce oxidative stress by increasing catalase enzyme activity in the kidneys and increasing glutathione in the liver and kidneys (Arunima & Rajamohan, 2013; Zakaria et al., 2011). VCO could also protect the kidney from nephrotoxicity by blocking oxidative stress, inflammation, and apoptosis and by downregulating the signaling pathway of NF- κ B/iNOS/caspase (Famurewa et al., 2020). There is no previous study yet showing the effect of the oil on malaria infection. Thus, this study aimed to explore the possible nephroprotective effect of VCO supplementation against *Plasmodium berghei* ANKA infection in mice.

MATERIAL AND METHODS

Experimental animal and parasite strain

Thirty-five male Balb/c mice (25-35 g) were obtained from and maintained at the Animal House, Department of Biochemistry, Universitas Airlangga, Surabaya, Indonesia. These animals were acclimatized for two weeks in a group of seven in cages with wooden shaves for bedding material. They were fed with a standard pellet diet and drinking water *ad libitum*. They were also maintained under standard laboratory conditions and subjected to a natural photoperiod of 12 hours light/ 12 hours dark cycle. This study meets the ethics requirements for research in experimental animals and is approved by the ethical committee clearance for preclinical research Universitas Airlangga with registration number 745/HRECC.FODM/XI/2019.



The asexual blood-stage *Plasmodium berghei* ANKA strain parasites were maintained *in vivo* in mice. The parasite were obtained from the Department of Parasitology, Universitas Airlangga, Surabaya, Indonesia. Each mouse was inoculated intraperitoneally with 0.2 ml of infected blood containing 1×10^7 infected erythrocyte/IE from donor mice with rising parasitemia of 30-45%.

Virgin coconut oil

The VCO used was by trade name Javara®, obtained from the supermarket in Surabaya City, East Java, Indonesia with BPOM RI MD no. 207928001388. According to the producer, Javara® is made from a fresh coconut through the cold press without additives.

Experimental design and treatment of mice

Thirty-five *P. berghei* infected mice were randomly divided into five groups (two control and three experimental groups), each having seven mice (Table 1). The animals in G1 were designated as negative control and received distilled water; G2 as a positive control (received DHP at the dose of 187,2 mg/kg body weight); G3-G5 as experimental groups with VCO treatment at the dose of 1, 5, and 10 ml/kg body weight/day, respectively. The VCO dose used in this research was based on the previously conducted study (Zakaria et al., 2011). The administrations of different treatments were given orally by using a standard intragastric tube once daily for four consecutive days (D0-D3). All animals were sacrificed 24 hours after the last treatment.

Serum biochemical Analysis

Twenty-four hours after the last dose of treatment or at D4, the mice were sacrificed, and the blood samples were collected by heart puncture. The blood sample for serum biochemical analysis of kidney function consisting of BUN and creatinine (Table 2) were collected in a vacutainer and analyzed using an automated machine (Dimension EXL-Siemens).

Histopathological study

The kidney was obtained from each mouse after twenty-four hours of the last dose of treatment or at D4. The kidney was washed and then fixed in 10% formal saline. The fixed tissues were then embedded in paraffin, sectioned ($5 \mu\text{m}$) with a rotary microtome, and stained with hematoxylin and eosin (H&E). The kidney sections were evaluated histologically with a camera attached to a light microscope (Nikon Eclipse) and NIS Element F 4.60.00 64bit software. The extent of *P. berghei*-induced kidney damage was evaluated based on pathologic lesions in kidney sections stained with the H&E method.

Statistical Analysis

The data were expressed in median (minimum-maximum). The value of the treated and control groups was compared using Kruskal Wallis parametric test with $p < 0.05$ being considered significant, using the IBM SPSS Statistic 23 for Mac.

Table 1. Grouping of animals and treatment

Groups	Treatment
G1	Untreated infected control (negative control). They were fed with distilled water
G2	Infected with <i>P. berghei</i> and treated with DHP (positive control)
G3	Infected with <i>P. berghei</i> and treated with VCO 1 ml/kg BW/day
G4	Infected with <i>P. berghei</i> and treated with VCO 5 ml/kg BW/day
G5	Infected with <i>P. berghei</i> and treated with VCO 10 ml/kg BW/day

VCO: virgin coconut oil, DHP: dihydroartemisinin + piperaquine; kg BW = kilogram body weight



RESULT

1. The Effect of VCO on Serum Biochemical Parameter

Table 2 presents the effect of a VCO supplemented diet on the kidney function of *P. berghei* ANKA infected mice. The BUN and creatinine serum are the markers of renal function. The BUN levels in all treatment groups are still within the normal reference value range (Charles River, 2012). The BUN levels in the G3 and G5 groups were lower than those in the group that was not given VCO (G1) or in the group given DHP (G2). This shows that VCO administration causes lower BUN levels. The analysis of differences in BUN levels was performed using the non-parametric Kruskal-Wallis test ($p = 0.018$), followed by the Mann-Whitney post hoc

test. The results of the Mann-Whitney test for BUN levels showed that there was a significant difference between the G3 group compared to the other groups.

The creatinine levels in all treatment groups are still within the normal reference value range (Charles River, 2012). This shows that in *P. berghei* ANKA infection, creatinine levels do not rise above normal values. The creatinine levels in the G4 and G5 groups were lower than those in the G1 and G2 control groups (Figure 2). The analysis of differences in creatinine levels was performed using the non-parametric Kruskal-Wallis test. The Kruskal-Wallis test results showed $p = 0.388$, which means that there was no significant difference between treatment groups so that further tests were not carried out.

Table 2. Evaluation of kidney function test in various experimental group on day 4

Group	BUN	Creatinin
G1 (untreated, distilled water)	16 (14 – 28)	0,32 (0,16 – 0,66)
G2 (DHP)	16 (13 – 20)	0,36 (0,18 – 0,38)
G3 VCO 1 ml/kgBW/day	14 (9 – 15)*,a,b,c,d	0,46 (0,18 – 0,72)
G4 VCO 5 ml/kgBW/day	16 (14 – 24)	0,27 (0,11 – 0,60)
G5 VCO 10 ml/kgBW/day	15 (14 – 20)	0,26 (0,19 – 0,42)

Values are median (minimum – maximum).

The normal value of BUN = 18 mg/dl and creatinine = 0,4 mg/dL (Charles River, 2012).

The * sign shows significant differences with $p < 0,05$, a compared to G, b compared to G2, c compared to G3, d compared to G4, and e compared to G5.

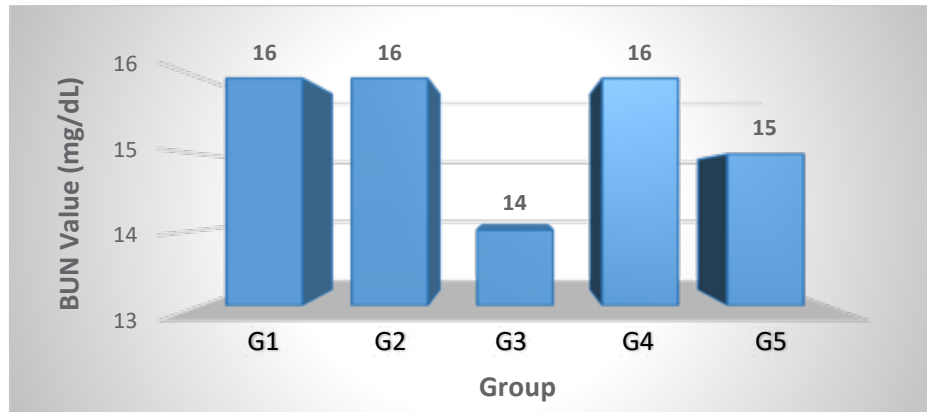


Figure 1. Comparison of BUN in *P. berghei* ANKA infected mice

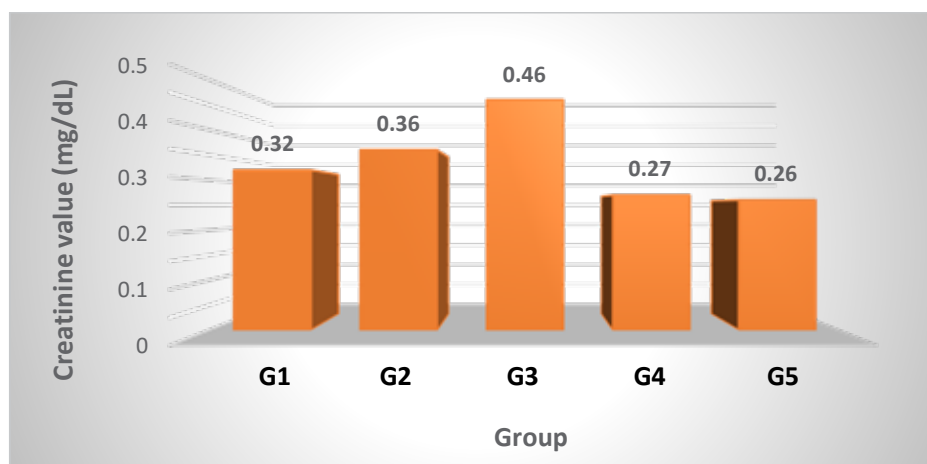


Figure 2. Comparison of creatinine in *P. berghei* ANKA infected mice

2. Histopathological Study of the Kidney of *P. berghei* infected mice Treated with VCO

The effect of VCO supplementation on renal histology is presented in Table 3. The histopathological alteration in the kidney was tubular necrosis (yellow arrow) that can be observed in the medulla and cortex, glomerulonephritis (yellow triangle), and interstitial nephritis (yellow rectangle). The treatment with VCO shows mild changes compared to the control groups.

Table 3 shows that acute tubular necrosis in the kidneys of mice between treatment groups is significantly different ($p = 0.007$). The Mann-Whitney post hoc test results showed significant

differences between all VCO treatment groups (G3, G4, and G5) compared to the G1 group. All mice kidneys in the VCO treatment group only showed mild acute tubular necrosis (100%); that is, there was only a change of less than 10%. This is different from the G1 group, which showed mild necrosis with changes of 10-25% (42.9%) and moderate necrosis with changes of 26% -75% (57.1%), while the necrosis that occurred in the G2 group mainly was mild (85.7%) and only 14.3% were moderate.

The glomerulonephritis in the kidneys of mice between treatment groups is significantly different ($p = 0.015$). The Mann-Whitney post

hoc test results showed that all VCO treatment groups (G3, G4, and G5) were significantly different compared to the G1 group. Glomerulonephritis in the VCO group mostly showed mild changes in contrast to changes in the G1 group, where most of them experienced moderate changes. The group showing mild glomerulonephritis, an alteration of less than 30%, was 71.4%, while the group that showed moderate alteration was 22.9%. The kidneys of mice that presented no glomerulonephritis were 5.7%.

The interstitial nephritis that occurred between the treatment groups was not significantly different ($p = 0.131$). The kidneys of mice that showed mild interstitial nephritis were 54.3% less than 30%, moderate changes were 30-50% at 31.4%, and severe changes were 2.9%. There were 11.4% of mice that did not experience changes in interstitial nephritis in the G2, G3, and G5 groups.

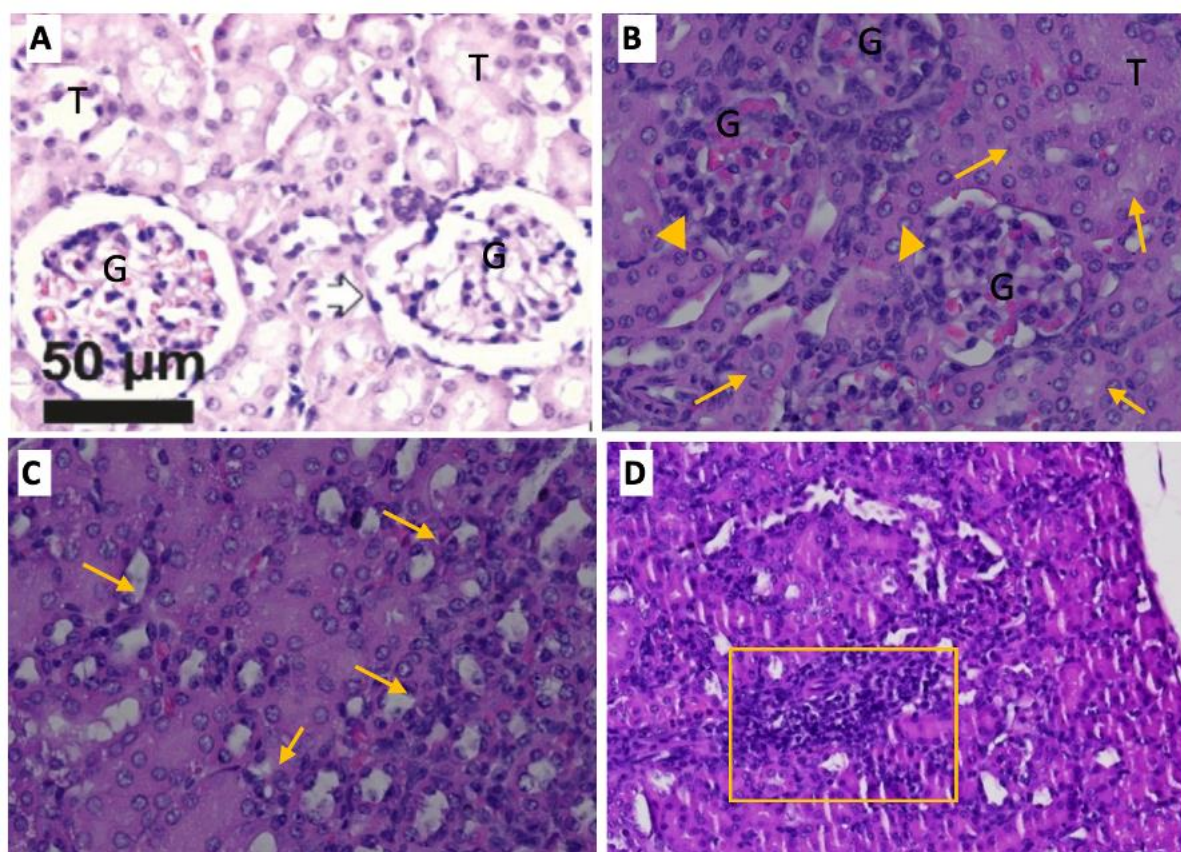


Figure 3. The histologic photomicrograph was observed in *P. berghei* ANKA infected mice with HE stain. Figure A shows a normal kidney with 400x magnification (Source: Lopes et al., 2018); B and C shows 400x magnification and D with 100x magnification. Figure B shows acute tubular necrosis (yellow arrow) and glomerulonephritis (yellow triangle) located in the cortex, Figure C shows tubular necrosis in the medulla; and Figure D shows interstitial nephritis (rectangle).



QANUN MEDIKA

JURNAL KEDOKTERAN FKUM SURABAYA

<http://journal.um-surabaya.ac.id/index.php/qanunmedika>



DISCUSSION

Kidney dysfunction could be assessed by looking at the alteration in kidney biochemical parameters, namely BUN and creatinine. Particular diseases or medications could cause those alterations. However, several studies showed that VCO could protect the kidney from such alteration (Akinnuga et al., 2014; Famurewa et al., 2020; Nwafor et al., 2020; Sinaga et al., 2019). Daily administration of the oil can significantly reverse the degenerating and destructive effects of diabetes in Wistar rats' kidneys through antioxidant and anti-inflammatory mechanisms (Akinnuga et al., 2014). The phyto-oxidants in VCO could also protect the Wistar rats' kidneys against the paraquat nephrotoxicity in a dose-dependent manner (Nwafor et al., 2020). Administration of VCO can also reduce levels of urea and creatine when rats perform maximum physical activity (Sinaga et al., 2019). The VCO diet also inhibited the renal damage caused by gentamicin with a significant decrease in kidney serum markers (Famurewa et al., 2020).

The effect of VCO on the kidneys in this study was assessed by assessing the alteration in renal histopathology, BUN, and creatinine. The group that was given VCO showed better results than without VCO in the kidneys of mice infected with *P. berghei* ANKA. This result was due to the nephroprotective effect of VCO, as shown in research with methotrexate or gentamycin induction (Famurewa et al., 2017, 2020).

Impaired renal function is characterized by levels of BUN and creatinine exceeding the normal reference limit. This study showed that *P. berghei* ANKA's acute infection did not cause high BUN and creatinine levels in all treatment groups. The two renal biochemical parameters in all treatment groups were still within the normal reference limit. Different results were found in several other studies (Adetutu et al., 2016; Elias et al., 2012). The results of BUN

and creatinine in this study indicate that there has been no impairment of renal function as indicated by the value of these two parameters is still below the normal reference or only slightly increases (Charles River, 2012). The effect of VCO administration resulted in lower BUN in the G3 and G5 groups than in the group not given VCO (G1), so it can be concluded that VCO has nephroprotective potential.

Two things mainly cause the alteration that occurs in the kidneys. First, the attachment of *Plasmodium*-infected erythrocytes to the endothelium, and the second one is the rosette phenomenon, which is an infected erythrocyte clotted with normal erythrocytes (Barsoum, 2000; Rowe et al., 2009). Both of these can interfere with microcirculation (Sriboonvorakul et al., 2018). This condition is associated with hemodynamic abnormalities such as hypovolemia and shock (Silva Junior et al., 2017), followed by endothelial activation, accompanied by the release of cytokines and several other inflammatory mediators that play a role in the mechanism of renal impairment in malaria. In addition to cytoadherence, there is also activation of the host's immune response to oxidative stress products during infection (Adetutu et al., 2016). Therefore, giving VCO containing antioxidants can reduce further oxidative damage due to reactive oxygen species.

The histopathological examination of the kidneys observed in this study was acute tubular necrosis, interstitial nephritis, and glomerulonephritis. In this study, there were mild to moderate glomerular and tubular abnormalities (Table 3). Tubular necrosis and glomerulonephritis in the three VCO groups were milder than those in the G1 group, which did not receive VCO. The BUN and creatinine parameters are still within normal limits even though there have been histopathological changes in the kidneys. This shows that the clinical biochemical renal function is still



good (Table 2). The changes in kidney histopathology in the form of acute tubular necrosis in the VCO treatment group are milder than the G1 control group, so it can be concluded that the severity of tubular necrosis that occurs in *P. berghei* ANKA infection can be reduced by giving VCO or VCO has nephroprotective potential.

There are some of the limitations of this study. There is no analysis of the VCO content fraction/ isolate and no analysis of oxidative stress markers (such as malondialdehyde and catalase). Both analyses should be performed in the future to better understand the effect of VCO antioxidants in malaria infection.

CONCLUSION

The VCO has a nephroprotective potential in *P. berghei* ANKA infection. Acute tubular necrosis and glomerulonephritis in the three VCO groups were milder than those in the G1 group. The BUN levels in the G3 group (treated with VCO at a dose of 1 ml/kgBW/day) were significantly different from other groups.

Based on the research process that researchers in this study have undertaken, what needs to be done is to analyze the fraction/isolate of VCO content and analysis of oxidative stress markers so that the effect of antioxidants on kidney function can be better understood.

ACKNOWLEDGEMENT

The fund from Universitas Muhammadiyah Surabaya fully supported this research. The authors gratefully appreciate the institution for allowing the use of facilities for this research.

CONFLICT OF INTEREST

The authors declare no conflict of interest.

REFERENCE

- Adetutu, A., Olorunnisola, O. S., Owoade, A. O., & Adegbola, P. (2016). Inhibition of in vivo growth of *Plasmodium berghei* by *Launaea taraxacifolia* and *Amaranthus viridis* in mice. *Malaria Research and Treatment*, 2016, e9248024. <https://doi.org/10.1155/2016/9248024>
- Akil, S. N. H. (2019). The clinical and histopathological aspect of the liver, lung, and kidney in Malaria. *Qanun Medika - Medical Journal Faculty of Medicine Muhammadiyah Surabaya*, 3(2), 123-135-135. <http://dx.doi.org/10.30651/jqm.v3i2.2833>
- Akinnuga, A. M., Jeje, S. O., Bamidele, O., Amaku, E. E., Otogo, F. O., & Sunday, V. E. (2014). Virgin Coconut Oil: Remedial Effects on Renal Dysfunction in Diabetic Rats. *Physiology Journal*, 2014, e495926. <https://doi.org/10.1155/2014/495926>
- Arunima, S., & Rajamohan, T. (2013). Effect of virgin coconut oil enriched diet on the antioxidant status and araoxonase 1 activity in ameliorating the oxidative stress in rats – a comparative study. *Food and Function*, 4, 1402–1409.
- Barsoum, R. (2000). Malarial Acute Renal Failure. *Journal of the American Society of Nephrology*, 11(11). <https://jasn.asnjournals.org/content/11/11/2147.long>
- Charles River. (2012). *BALB/C Mouse Biochemistry*. www.criver.com
- Durasevic, S., Jasic, N., Prokic, M., Grigorov, I., Martinovic, V., Djordjevic, J., & Pavlovic, S. (2019). The protective role of virgin coconut oil on the alloxan-induced oxidative stress in liver, kidney and heart of diabetic rats. *Food and Function*. <https://sci-hub.se/https://pubs.rsc.org/en/content/articlelanding/2019/fo/c9fo00107g#!divAbstract>



QANUN MEDIKA

JURNAL KEDOKTERAN FKUM SURABAYA

<http://journal.um-surabaya.ac.id/index.php/qanunmedika>



- Elias, R. M., Correa-Costa, M., Barreto, C. R., Silva, R. C., Hayashida, C. Y., Castoldi, Â., Gonçalves, G. M., Braga, T. T., Barboza, R., Rios, F. J., Keller, A. C., Cenedeze, M. A., Hyane, M. I., D'Império-Lima, M. R., Figueiredo-Neto, A. M., Reis, M. A., Marinho, C. R. F., Pacheco-Silva, A., & Câmara, N. O. S. (2012). Oxidative Stress and Modification of Renal Vascular Permeability Are Associated with Acute Kidney Injury during *P. berghei* ANKA Infection. *PLoS ONE*, 7(8). <https://www.ncbi.nlm.nih.gov/pmc/articles/PMC3432099/>
- Famurewa, A. C., Aja, P. M., Maduagwuna, E. K., Ekeleme-Egedigwe, C. A., Ufebe, O. G., & Azubuike-Osu, S. O. (2017). Antioxidant and anti-inflammatory effects of virgin coconut oil supplementation abrogate acute chemotherapy oxidative nephrotoxicity induced by anticancer drug methotrexate in rats. *Biomedecine & Pharmacotherapie*, 96, 905–911. <https://doi.org/10.1016/j.biopha.2017.12.008>
- Famurewa, A. C., Maduagwuna, E. K., Folawiyo, A. M., Besong, E. E., Eteudo, A. N., Famurewa, O. A., & Ejezie, F. E. (2020). Antioxidant, anti-inflammatory, and antiapoptotic effects of virgin coconut oil against antibiotic drug gentamicin-induced nephrotoxicity via the suppression of oxidative stress and modulation of iNOS/NF-κB/caspase-3 signaling pathway in Wistar rats. *Journal of Food Biochemistry*, 44(1), e13100. <https://doi.org/10.1111/jfbc.13100>
- Harijanto, P., Gunawan, C., & Nugroho, A. (2016). *Malaria, tatalaksana klinis dan terapi* (3rd ed.). Penerbit Buku Kedokteran EGC.
- Isa, Rinidar, & Sugito. (2013). Aktivitas Antiplasmodium Daun Sernai (*Wedelia Biflora*) Berdasarkan Evaluasi Fungsi Ginjal dan Hati pada Mencit yang Diinfeksi dengan *Plasmodium berghei*. *Jurnal Veteriner*, 13(2), 167–175.
- Kalia, S., Bagai, U., & Gorki, V. (2015). Effect of *Albizia lebbek* on liver and kidney function of *Plasmodium berghei* infected mice. *International Journal of Pharma Sciences and Research*, 6(3), 575–581.
- Kemenkes RI. (2016). *InfoDatin Malaria*.
- Koopmans, L. C., Wolfswinkel, M. E. van, Hesselink, D. A., Hoorn, E. J., Koelewijn, R., Hellemond, J. J. van, & Genderen, P. J. J. van. (2015). Acute kidney injury in imported *Plasmodium falciparum* malaria. *Malaria Journal*, 14(1), 1–7. <https://doi.org/10.1186/s12936-015-1057-9>
- Lopes, T. C. M., Silva, D. F., Costa, W. C., Frézard, F., Barichello, J. M., Silva-Barcellos, N. M., Lima, W. G. de, & Rezende, S. A. (2018). Accelerated Blood Clearance (ABC) Phenomenon Favors the Accumulation of Tartar Emetic in Pegylated Liposomes in BALB/c Mice Liver. *Pathology Research International*. <https://doi.org/10.1155/2018/9076723>
- Menard, D., & Dondorp, A. (2017). Antimalarial Drug Resistance: A Threat to Malaria Elimination. *Cold Spring Harbor Perspectives in Medicine*, 7(7). <https://doi.org/10.1101/cshperspect.a025619>
- Nwafor, J., Umudu, J., Oviosun, A., & Uchewa, O. (2020). EFFECT OF VIRGIN COCONUT OIL ON THE KIDNEY OF WISTAR RATS EXPOSED TO A TOXIC DOSE OF PARAQUAT. *International Journal of Medical Reviews and Case Reports*, 5.



- Phillips, M. A., Burrows, J. N., Manyando, C., van Huijsduijnen, R. H., Van Voorhis, W. C., & Wells, T. N. C. (2017). Malaria. *Nature Reviews Disease Primers*, 3(1), 17050. <https://doi.org/10.1038/nrdp.2017.50>
- Plewes, K., Royakkers, A. A., Hanson, J., Hasan, M. M. U., Alam, S., Ghose, A., Maude, R. J., Stassen, P. M., Charunwatthana, P., Lee, S. J., Turner, G. D., Dondorp, A. M., & Schultz, M. J. (2014). Correlation of biomarkers for parasite burden and immune activation with acute kidney injury in severe falciparum malaria. *Malaria Journal*, 13, 91.
- Rowe, J. A., Claessens, A., Corrigan, R. A., & Arman, M. (2009). Adhesion of Plasmodium falciparum-infected erythrocytes to human cells: Molecular mechanisms and therapeutic implications. *Expert Reviews in Molecular Medicine*, 11. <https://doi.org/10.1017/S1462399409001082>
- Silva Junior, G. B. da, Pinto, J. R., Barros, E. J. G., Farias, G. M. N., Daher, E. D. F., Silva Junior, G. B. da, Pinto, J. R., Barros, E. J. G., Farias, G. M. N., & Daher, E. D. F. (2017). Kidney involvement in malaria: An update. *Revista Do Instituto de Medicina Tropical de São Paulo*, 59. <https://doi.org/10.1590/s1678-9946201759053>
- Sinaga, F. A., Harahap, U., Silalahi, J., & Sipahutar, H. (2019). Antioxidant Effect of Virgin Coconut Oil on Urea and Creatinine Levels on Maximum Physical Activity. *Open Access Macedonian Journal of Medical Sciences*, 7(22), 3781–3785. <https://doi.org/10.3889/oamjms.2019.503>
- Sriboonvorakul, N., Ghose, Hassan, Hossain, Faiz, Pukrittayakamee, Chotivanich, Sukthana, Leopold, Plewes, Day, White, Tarning, & Dondorp. (2018). Acidosis and acute kidney injury in severe malaria. *Malaria Journal*, 17(128).
- WHO. (2015). *Guidelines for the treatment of malaria*.
- WHO. (2018). *World malaria report 2018*.
- Zakaria, Z. A., Rofiee, M. S., Somchit, M. N., Zuraini, A., Sulaiman, M. R., Teh, L. K., Salleh, M. Z., & Long, K. (2011). Hepatoprotective activity of dried- and fermented-processed virgin coconut oil. *Evidence-Based Complementary and Alternative Medicine: ECAM*, 2011, 142739. <https://doi.org/10.1155/2011/142739>